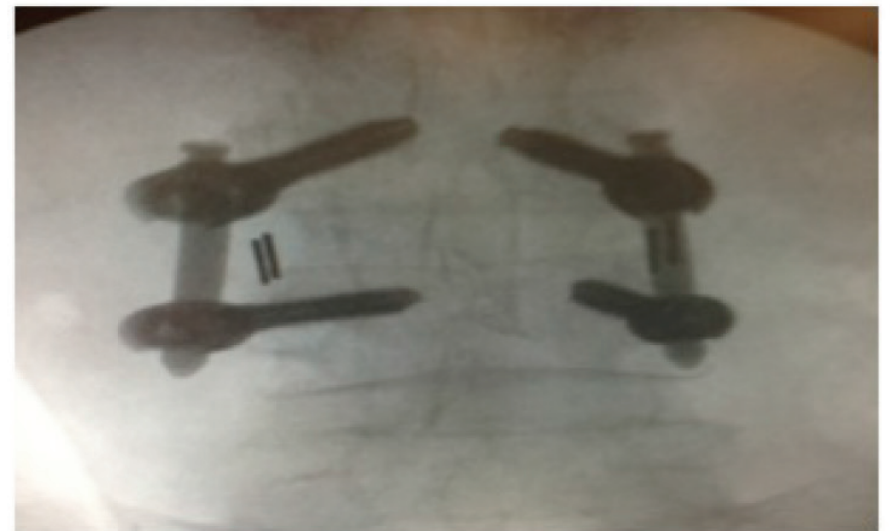
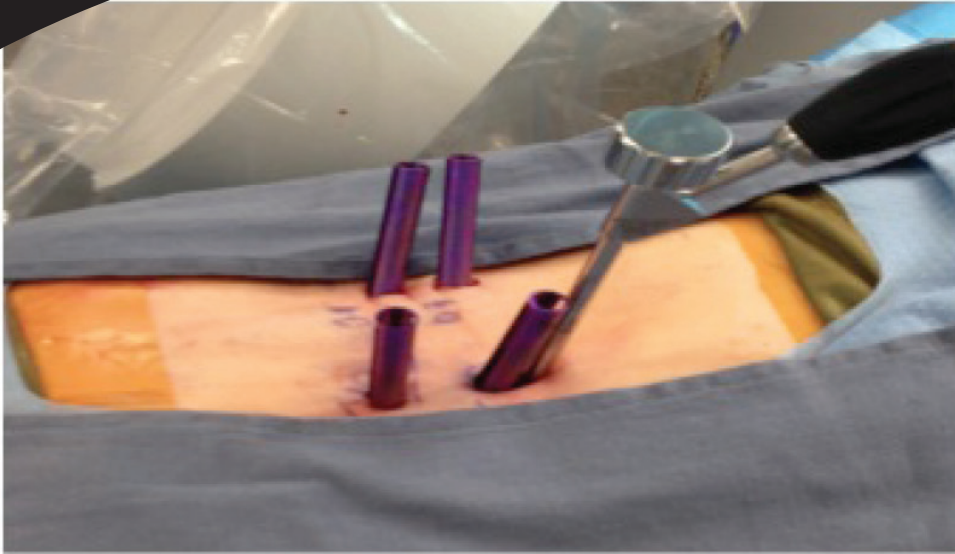


MIS Case 1

Elderly with DDD & Stenosis L3/4



MIS Case 2

60 y/o with DDD & HNP L3/L4

